

# C-shaped root canal system in mandibular second molars in a Chinese population evaluated by cone-beam computed tomography

Q. Zheng<sup>1</sup>, L. Zhang<sup>1</sup>, X. Zhou<sup>2</sup>, Q. Wang<sup>1</sup>, Y. Wang<sup>1</sup>, L. Tang<sup>1</sup>, F. Song<sup>3</sup> & D. Huang<sup>2</sup>

<sup>1</sup>State Key Laboratory of Oral Diseases, Sichuan University, Chengdu; <sup>2</sup>Department of Conservative Dentistry and Endodontics, West China College of Stomatology, Sichuan University, Chengdu; and <sup>3</sup>State Key Laboratory of Nonlinear Mechanics (LNM), Institute of Mechanics, Chinese Academy of Sciences, Beijing, China

## Abstract

**Zheng Q, Zhang L, Zhou X, Wang Q, Wang Y, Tang L, Song F, Huang D.** C-shaped root canal system in mandibular second molars in a Chinese population evaluated by cone-beam computed tomography. *International Endodontic Journal*, **44**, 857–862, 2011.

**Aim** To evaluate the anatomical features of C-shaped canal systems in Chinese mandibular second molars by cone-beam computed tomography (CBCT).

**Methodology** A total of 608 patients of Chinese descent with healthy, well-developed mandibular second molars were enrolled. These patients were referred to the West China Hospital of Stomatology and required radiographic examination by CBCT as part of their routine dental treatment. Of the 608 examined CBCT images, 528 showed unilateral intact molars and 80 showed bilateral intact molars. Bilateral molar data were only used to analyse the distribution of unilateral and bilateral occurrences of C-shaped canals. The following *in vivo* CBCT observations were made: (i)

frequency and type of root; (ii) frequency of C-shaped canals by gender, age and tooth position (left versus right); (iii) the classification of cross-sectional canal images of C-shaped canals; and (iv) unilateral and bilateral occurrences of C-shaped canals.

**Results** Fused roots were present in 39% of molars. A C-shaped canal system was present in 39% of the teeth. This prevalence did not differ with gender, age and tooth position. Most (81%) of the C-shaped canals in individuals with bilateral molars were symmetrical. Most of the canals with uninterrupted 'C'-shapes appeared to divide into two or more canals towards the canal terminus.

**Conclusion** There was high prevalence of C-shaped canals in the mandibular second molars of Chinese population. The canal systems varied considerably in their anatomical configuration.

**Keywords:** cone-beam computed tomography, C-shaped canals, mandibular second molar, root and canal anatomy.

Received 12 January 2011; accepted 28 April 2011

## Introduction

Knowledge of root canal anatomy and variations between ethnic groups is essential for clinicians to facilitate effective root canal treatment (RCT) (Vertucci 1984). Of particular interest is the canal configuration of the mandibular second molar. Predicting and negotiating a C-shaped root canal configuration is chal-

lenging. Manning (1990) speculated that the failure of the Hertwig's epithelial root sheath to fuse on the lingual or buccal root surface was the main cause of a C-shaped root, which always contains a C-shaped canal. The main feature of this variation is the presence of a fin or web connecting the individual root canals to form a letter 'C' shape at the root canal orifice.

The C-shaped canal is most frequently found in the mandibular second molar. It is a significant ethnic variation that has a high prevalence in Asians (Yang *et al.* 1988, Seo & Park 2004). Melton *et al.* (1991) first proposed the classification of C-shaped canals based on their cross-sectional shape. However, there was no

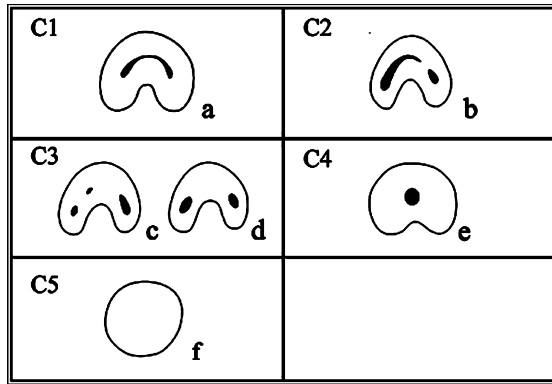
Correspondence: Ding-ming Huang, Department of Conservative Dentistry, West China College of Stomatology, Sichuan University, Chengdu, 610041, China (Tel.: +86-28-85501481; e-mail: dingminghuang@163.com).

clear description of how to differentiate between Category II and Category III. Fan *et al.* (2004) analysed the morphology of C-shaped canals in mandibular second molars using microcomputed tomography (micro-CT) and modified Melton's method (Figs 1 and 2).

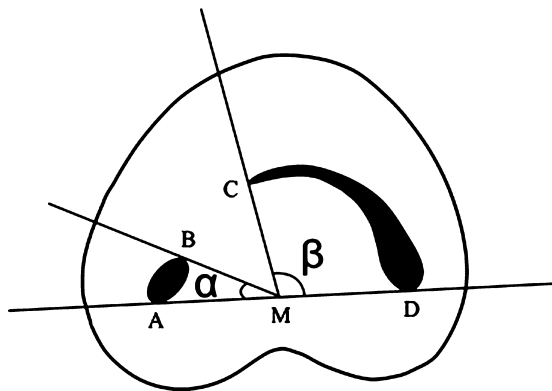
Most of the investigations concerning the anatomic characteristics of C-shaped canals were invasive studies and were conducted with extracted teeth. As a non-invasive three-dimensional (3D) imaging technique, cone-beam computed tomography (CBCT) was reported

to be sufficiently precise for morphological analysis (Neelakantan *et al.* 2010, Zhang *et al.* 2010). Compared with conventional medical computed tomography, studies using CBCT can be accomplished with a substantially lower effective dose and shorter working time (Patel *et al.* 2007).

This study aimed to evaluate the prevalence and types of C-shaped canals in permanent mandibular second molars in a Chinese population using CBCT. The cross-sectional characteristics of roots with C-shaped canals were evaluated by gender, age and tooth position (left versus right). The unilateral and bilateral occurrences of C-shaped canals were also considered.



**Figure 1** Classification of C-shaped canal configuration. C1: continuous C-shaped canal. C2: MB-D canal and an ML canal. C3a: two separate canals. C3b: three separate canals. C4: single round or oval canal. C5: no canal lumen could be observed (which was usually seen near the apex only) (Fan *et al.* 2004).



**Figure 2** Measurement of angles for the C2 canal. Angle  $\beta$  is more than  $60^\circ$ . (a and b) Ends of one canal cross-section; (c and d) ends of the other canal cross-section; M, middle point of line AD;  $\alpha$ , angle between line AM and line BM;  $\beta$ , angle between line CM and line DM (Fan *et al.* 2004).

## Materials and methods

Cone-beam computed tomography images of 688 mandibular permanent second molars from 608 individuals of Chinese descent were identified in the database of the medical imaging centre in the West China Hospital of Stomatology, Chengdu, China. These individuals were referred to this hospital between May 2009 and August 2010 and required radiographic examination by CBCT as part of their dental treatment. The images were taken as part of the routine examination, diagnosis and treatment planning. Informed consent was obtained from the patients, and this study was approved by the Ethics Committee of the West China Hospital of Stomatology.

Mandibular molars included in this study had fully formed apices and lacked root fillings, posts and crown restorations. Of the study population, 528 individuals had unilateral molars (i.e. CBCT images revealed only one intact molar), whilst 80 individuals had bilateral molars (i.e. CBCT images revealed two opposite intact molars). Bilateral molar data were used only to analyse the distribution of unilateral and bilateral occurrences of C-shaped canals.

The 3D Accuitomo CBCT machine [MCT-1(EX-2F); J. Morita Manufacturing Corp., Kyoto, Japan] used for tooth identification provided a gray-scale image of 14 bits and had a voxel size of 0.125 mm. All images used a 1-mm slice thickness. The machine operated at 80 kV and 5.0 mA, with a 17-second exposure time.

Axial, coronal and sagittal two-dimensional section images were displayed on a monitor and inspected by two endodontists using One Volume Viewer software (J. Morita Manufacturing Corp.). If a consensus could not be reached between the two examiners, an oral radiologist would assist in making the decision. The C-shaped canals were collected and categorized according to the

existing classification (Fan *et al.* 2004; Fig. 1). The definition of a C-shaped canal system in a mandibular second molar required that the tooth exhibit all of the following three features: (i) fused roots; (ii) a longitudinal groove on the lingual or buccal surface of the root; and (iii) at least one cross-section of the canal belonging to the C1, C2 or C3 configuration (Fan *et al.* 2004).

The frequency of the numbers of root and C-shaped canals and the correlations with gender, age and tooth position (left side or right side) were determined and assessed by the chi-squared test. The bilateral and unilateral appearances of C-shaped canals were recorded.

The scanned cross-sectional canal images at the level of the canal orifice, coronal third portion (from the orifice to the coronal 1/3 point of canal length), middle third portion (from the coronal 1/3 point of canal length to the apical 1/3 point of canal length), and apical third portion (from the apical 1/3 point of canal length to the apical foramen) were assessed and classified for each tooth according to the classification by Fan *et al.* (2004).

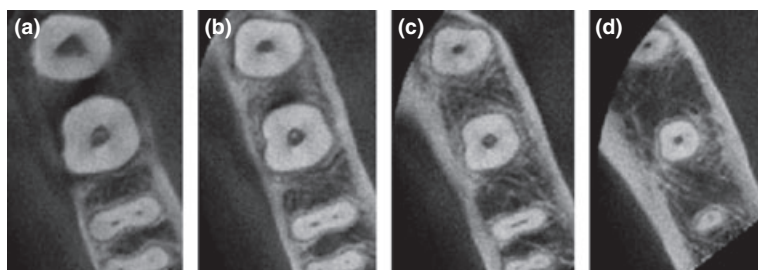
## Results

The 528 individuals with unilateral mandibular second molars were between 13 and 74 years of age, with a mean age of 40.1 years. Table 1 shows the frequency

**Table 1** Frequency distribution of root morphology in mandibular second molars

Root morphology	Mandibular second molars ( <i>n</i> = 528), %
All roots separate	321 (60.1)
Fused roots	
with buccal groove	0 (0)
with lingual groove	116 (22.0)
with both buccal and lingual grooves	91 (17.2)
Total	528 (100)

**Figure 3** Example of cone-beam computed tomography images of a tooth with an oval canal. (a) Canal orifice, (b) Coronal third level, (c) Mid-root, (d) Apical third level.



**Table 2** Frequency of C-shaped canals in mandibular second molars

	C-shaped	Normal*	Total
	204	324	528
Proportion (%)	38.6	61.4	100

\*Teeth with root canal system not belonging to C-shape.

distribution of root morphology in mandibular second molars. Of the 528 teeth, 207 had fused roots. Amongst those teeth with fused roots, 116 had only one longitudinal groove on the lingual root surface, whereas the other 91 had one shallow buccal and one deep lingual groove. In the 207 teeth with root fusion, 204 teeth had a C-shaped canal system somewhere along their length, whereas three had a single round or oval canal throughout (Table 2, Fig. 3).

Table 3 shows the distribution of C-shaped canal systems in the mandibular second molars by gender, age and tooth position. No statistical differences were observed in these data.

The cross-sectional shape of C-shaped canals at different root levels is shown in Table 4 (Fig. 4). The majority of canal orifices (73%) demonstrated an uninterrupted 'C' shape, followed by a C2-type orifice (18%), and 9% of the C-shaped canals presented with the C3 shape (Table 3). All three of the teeth without a C-shaped canal had oval or round orifices. The majority of cross-sections with an uninterrupted C-shape and a semicolon shape were found in the coronal part of the root. Separated canals appeared more apically in the root.

Table 5 shows the changes in root canal cross-sectional classification at different levels. The classification type of 94% of the C-shaped canals changed between two adjacent levels.


The distribution of the unilateral and bilateral occurrences of C-shaped canals amongst individuals with bilateral qualifying permanent mandibular second molars is shown in Tables 6 and 7. Of the 608 individuals examined, 80 had bilateral permanent

**Table 3** Frequency of C-shaped canals in mandibular second molars by gender, age, and tooth position

	Gender		Tooth position		Age (years)					
	Male	Female	Left	Right	11-20	21-30	31-40	41-50	51-60	>60
	<i>n</i> = 297	<i>n</i> = 231	<i>n</i> = 312	<i>n</i> = 216	<i>n</i> = 45	<i>n</i> = 114	<i>n</i> = 99	<i>n</i> = 120	<i>n</i> = 87	<i>n</i> = 63
No. of teeth	108	96	120	84	15	39	45	45	36	24
Frequency (%)	36.4	41.6	38.5	38.9	33.3	34.2	45.5	37.5	41.4	38.1

**Table 4** Cross-sectional canal shapes of C-shaped canals at different levels

Root level	C1	C2	C3(c)	C3(d)	C4	Total
Orifice (%)	148 (72.5)	37 (18.1)	0 (0)	16 (7.8)	0 (0)	204 (100)
Coronal (%)	97 (47.5)	25 (12.3)	23 (11.3)	59 (28.9)	0 (0)	204 (100)
Middle (%)	13 (6.4)	36 (17.6)	65 (31.9)	80 (39.2)	0 (0)	204 (100)
Apical (%)	12 (5.9)	3 (1.5)	92 (45.1)	72 (35.3)	25 (12.3)	204 (100)



**Figure 4** Example of cone-beam computed tomography images of a tooth with a C-shaped canal system and its classification. (a) Canal orifice, C1. (b) Coronal third level, C2. (c) Mid-root, C3(c). (d) Apical third level, C3(d).

**Table 5** Number of C-shaped canals showing change in classification at different levels

	Number of teeth with C-shaped canal
Configuration remains unchanged	12
Configuration changing apically	192
Orifice to coronal level	101
Coronal to middle level	108
Middle to apical level	78

**Table 6** Distribution of unilateral and bilateral occurrences amongst 80 patients with C-shaped canals in the mandibular second molars

	Number of patients	Frequency (%)
C-shaped canal		
Unilateral, left	4	12.5
Unilateral, right	2	6.3
Bilateral	26	81.3
Total	32	100

mandibular second molars. The bilateral occurrence amongst individuals with C-shaped canals in mandibular second molars was 81%, which was much higher

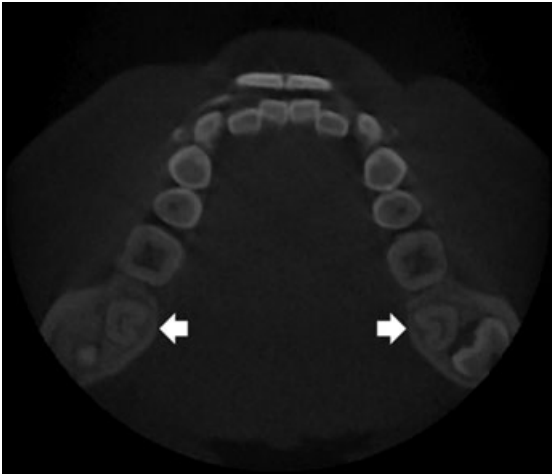
**Table 7** Distribution of unilateral and bilateral occurrences of C-shaped canals amongst 80 patients with bilateral permanent mandibular second molars

	C-shaped				Total
	Unilateral		Bilateral	Normal	
	Left	Right			
<i>n</i> (%)	<i>n</i> (%)	<i>n</i> (%)	<i>n</i> (%)	<i>n</i>	
No. of patients					
Male	2 (6.3)	0 (0.0)	10 (31.3)	20 (62.5)	32
Female	2 (4.2)	2 (4.2)	16 (33.3)	28 (58.3)	48
Total	4 (0.5)	2 (2.5)	26 (32.5)	48 (60.0)	80
No. of teeth	4 (2.5)	2 (1.3)	52 (32.5)	102 (63.8)	160

than the unilateral occurrence (19%) (Fig. 5). Frequency of bilateral distribution did not differ with gender and tooth position.

### Discussion

This study used CBCT to evaluate the root and canal systems of 688 mandibular second molars in 608 Chinese individuals. To ensure that the teeth were from a purely ethnic Chinese population, the CBCT images



**Figure 5** Example of cone-beam computed tomography images of a patient with a symmetrically distributed C-shaped canal system. The white arrows denote C-shaped canals.

were collected in this study only from indigenous Chinese individuals.

The definition of a C-shaped canal is not clear. Some authors considered C-shaped canals as all those with a general outline of a 'C' and present in a C-shaped root, regardless of whether a separate canal or orifice was observed (Al-Fouzan 2002). Fan *et al.* (2004) analysed the C-shaped canal system using micro-CT and modified the classification of the C-shaped canal system. They considered that this type of canal system had to exhibit all of the following three features: (i) fused roots; (ii) a longitudinal groove on the lingual or buccal surface of the root; and (iii) at least one cross-section of the canal belonging to the C1, C2 or C3 configuration. They found that although the C3-type orifice may look like two or three separate orifices, an isthmus linking them is often discernible. The definition and cross-sectional classification of C-shaped canals in this study followed Fan's method (Fan *et al.* 2004).

The current study revealed that 40% of the mandibular second molars had fused roots. This result was lower than that reported by Walker (1988), which showed that 52% of the sample of 100 extracted mandibular second molars in a Southern Chinese population had root fusion. It may be the sample size and study method that caused the differences. Most of the teeth with a C-shaped canal system, in this study, were found to have a deep lingual groove with or without a shallow buccal groove. This result was consistent with previously reported findings (Fan *et al.* 2004, Jin *et al.* 2006).

In the literature, the C-shaped canal was most common in a Korean population, with 31-45% prevalence (Seo & Park 2004, Jin *et al.* 2006). Yang *et al.* (1988) reported that 32% of the teeth in a Chinese population in their study had a C-shaped root (i.e. the cross-section of the root looks like the letter 'C'), whilst 14% of the teeth actually had a C-shaped root canal. However, in the present study, the prevalence of C-shaped canals was 39% in the Chinese population. It may be that the sample source, different definitions of C-shaped canals and the study methods were responsible for the differences.

A study of human permanent teeth from Turkish individuals (Sert & Bayirli 2004) reported that the possibility of the second premolars having a single root canal in females is almost twice that of males. They concluded that gender was an important factor to be considered in the preoperative evaluation of canal morphology for non-surgical RCT. In this study, no correlation was found between gender and the prevalence of C-shaped canals. This prevalence also did not differ with age and tooth position (left versus right).

Sabala *et al.* (1994) reported that, when present on one side, a C-shaped canal may be found in the contralateral tooth in over 70% of individuals. Similarly, it was found that C-shaped canals in this study were symmetrically distributed in 81% of the sample. If a person has a known C-shaped canal in one mandibular second molar, the dentist should be aware of the likelihood that a C-shape is present in the opposite molar. There was no difference in bilateral occurrence by gender or tooth position.

Melton *et al.* (1991) reported that C-shaped canals can vary in number and shape along the length of the root. The study by Fan *et al.* (2004) also showed the same result. Therefore, the clinical crown morphology or the appearance of the orifice may not be a good predictor of actual canal anatomy. In this study, the cross-sectional canal shape was analysed at four root levels including canal orifice, coronal, middle and apical third of the root. The result showed that only 12 teeth (5.5%) did not change canal type from the orifice to the apical region. The rest of the samples had two or more classifications in the four levels. The results agreed with those of Seo & Park (2004), in that there was no consistent change in classification in the area between two adjacent levels. Deep orifice preparation and careful probing with small files may facilitate a more accurate characterization of the C-shaped category (Jerome 1994). In this study, the prevalence of C1 and C2 types decreased from the

orifice down to the apical region, whilst that of C3 and C4 types increased. This indicated that the continuous (C1) and semicolon (C2) C-shapes have a high possibility of dividing into two or three canals in the middle and apical regions. This was in accordance with the previously reported results in a Chinese population (Fan et al. 2004). Seo & Park (2004), who analysed 96 mandibular second molars extracted from Korean patients, also drew a similar conclusion. C1 and C2 types were much more difficult to clean and shape than the C3- and C4-type canals. Perhaps alternative canal cleaning techniques, such as those which use ultrasonics, would be more effective in dealing with these teeth.

## Conclusion

There was a high prevalence of C-shaped canals in the mandibular second molars drawn from a sample of Chinese. This C-shaped canal system tends to vary considerably in their anatomical configuration and thus leads to difficulties in debridement, filling and restoration. CBCT is a clinically useful tool in the endodontic diagnosis and treatment.

## References

- Al-Fouzan KS (2002) C-shaped root canals in mandibular second molars in a Saudi Arabian population. *International Endodontic Journal* **35**, 499–504.
- Fan B, Cheung GS, Fan M, Gutmann JL, Bian Z (2004) C-shaped canal system in mandibular second molars: part I – anatomical features. *Journal of Endodontics* **30**, 899–903.
- Jerome CE (1994) C-shaped root canal systems: diagnosis, treatment, and restoration. *General Dentistry* **42**, 424–7.
- Jin GC, Lee SJ, Roh BD (2006) Anatomical study of C-shaped canals in mandibular second molars by analysis of computed tomography. *Journal of Endodontics* **32**, 10–3.
- Manning SA (1990) Root canal anatomy of mandibular second molars. Part II. C-shaped canals. *International Endodontic Journal* **23**, 40–5.
- Melton DC, Krell KV, Fuller MW (1991) Anatomical and histological features of C-shaped canals in mandibular second molars. *Journal of Endodontics* **17**, 384–8.
- Neelakantan P, Subbarao C, Subbarao CV (2010) Comparative evaluation of modified canal staining and clearing technique, cone-beam computed tomography, peripheral quantitative computed tomography, spiral computed tomography, and plain and contrast medium-enhanced digital radiography in studying root canal morphology. *Journal of Endodontics* **36**, 1547–51.
- Patel S, Dawood A, Ford TP, Whaites E (2007) The potential applications of cone beam computed tomography in the management of endodontic problems. *International Endodontic Journal* **40**, 818–30.
- Sabala CL, Benenati FW, Neas BR (1994) Bilateral root or root canal aberrations in a dental school patient population. *Journal of Endodontics* **20**, 38–42.
- Seo MS, Park DS (2004) C-shaped root canals of mandibular second molars in a Korean population: clinical observation and in vitro analysis. *International Endodontic Journal* **37**, 139–44.
- Sert S, Bayirli GS (2004) Evaluation of the root canal configurations of the mandibular and maxillary permanent teeth by gender in the Turkish population. *Journal of Endodontics* **30**, 391–8.
- Vertucci FJ (1984) Root canal anatomy of the human permanent teeth. *Oral Surgery, Oral Medicine, and Oral Pathology* **58**, 589–99.
- Walker RT (1988) Root form and canal anatomy of mandibular second molars in a southern Chinese population. *Journal of Endodontics* **14**, 325–9.
- Yang ZP, Yang SF, Lin YC, Shay JC, Chi CY (1988) C-shaped root canals in mandibular second molars in a Chinese population. *Dental Traumatology* **4**, 160–3.
- Zhang R, Yang H, Yu X, Wang H, Hu T, Dummer PM (2010) Use of CBCT to identify the morphology of maxillary permanent molar teeth in a Chinese subpopulation. *International Endodontic Journal* **44**, 162–9.